

Geometric analysis of female pelvic floor muscles by using manual segmentation

T.H. Da Roza & R. Natal Jorge & M. Parente, JMRS Tavares
IDMEC- Faculty of Engineering, University of Porto, Porto, Portugal

C. Saleme & M.P. Barbosa & A.L.S. Filho
Federal University of Minas Gerias, Belo Horizonte, Brazil

T. Mascarenhas & J. Loureiro
Faculty of Medicine, University of Porto, São João Hospital, Porto, Portugal

ABSTRACT: Magnetic Resonance Imaging (MRI) has been used in the diagnostic evaluation of the pelvic floor dysfunctions. MRI can contribute to generate 3D solids of pelvic floor muscles through manual segmentation. The aim of this study is to calculate the area and its moment of inertia of 8 female pelvic floor muscles by using manual segmentation technique. Based on CAD software manual segmentation was used. To build 3D reconstruction models, through of twenty consecutive images. The models were made through splines in each sketch, documenting changes in the pubovisceral muscle (a part from the pelvic floor muscles) from the pubis to coccyx. Two sketches were chosen and biomechanics properties like area and stiffness (moment of inertia) were acquired for each sketch used to generate the pubovisceral muscles. The moment of inertia of the pubovisceral muscle decreases following the order: anterior sketch and posterior sketch. Higher values for the moment of inertia can be encountered in anterior sketcher. This conclusion can lead to more stability in the anterior compartment of pelvic floor visceral.

1 INTRODUCTION

The pelvis is a major structure within the human body, which in conjunction with the sacrum, facilitates the transfer of the weight of the upper body to the hip joints. In addition muscles originating on the cortex of the pelvis allow balance to be maintained about a single hip joint for activities such as walking and running (Bergmann et al. 2001).

The female pelvic floor is an understudied region of the body from the biomechanical perspective. The term pelvic floor refers to all structures that support and position the pelvic organs (Stoker et al. 2008). It is a fibromuscular sheet that runs from the symphysis pubis to the coccyx and sacrum forming the inferior and dorsal walls of the pelvis (Reis et al. 2002).

Pelvic floor muscles (PFM) play an essential role in the support and functioning of the pelvic organs. Among the main components of support has been the muscle pubovisceral, also called pubococccígeo, subdivided into muscles puboperineal, pubovaginal, puboanal, pubourethral and iliococccígeo (Stoker et al. 2008).

The function of the pelvic floor is related to the ability to perform a contraction, this means a contraction in mass which implies a lifting and closing the meatus urethral vaginal and anal (Bo et al. 2005). Each of the pelvic floor muscles have different fiber directions, and if each of these muscles

could contract individually, they produce different functions (Bo 2004).

Pelvic floor muscles dysfunction encompasses common conditions that negatively impact the lives of millions of women worldwide. These conditions include urinary and fecal incontinence, pelvic organs prolapse, pelvic pain, and sexual dysfunction (Olsen et al. 1997). Among the most common disorders found is urinary incontinence the most prevalent and distressing health problem which has been reported to affect 35% of adult women (Hunskar et al. 2004). About 50% of parous women have some degree of pelvic organ prolapse (Subak L.L. 2001) although only 10% are symptomatic (Oslen et al. 1997).

Conservative treatment, like physiotherapy, is advised to the treatment of these pathologies (Bump 1991). If a muscle is weak, it can be strengthened. If a portion of the muscle is partially denervated then the remaining muscle part can be recruited to compensate for its muscle loss (Bo and Sherburn, 2005).

The exercises of voluntary contraction of the pelvic floor are the basis of treatments of physical therapy presenting many benefits, such as: improving body perception and awareness of pelvic region, increased vascularization of the pelvic region, increasing the tone and muscle strength of the floor; improvement biomechanics of the pelvic muscles and keeping the group stronger (Petricelli, 2003). Bo (2003) shows in her study that training the muscles

of pelvic floor find cure rates, measured as <2g of leakage on pad testing, varies between 44% and 70. In addition, there is evidence from two randomized controlled trials that training these muscles may also be effective in the treatment of pelvic organ prolapse (Hagen et al 2006 and Piya-Anant et al. 2003).

The accurate assessment and measurement of symptoms relating to pelvic floor disorders is essential for clinical diagnosis and monitoring of outcome (Ghoniem et al. 2008). Magnetic Resonance Imaging (MRI) has been used in the diagnostic evaluation of the pelvic floor dysfunctions. Recent advances in MRI has provided evidence of localized muscle injury in an individual, so it will be possible to better understand the relationship between injury to a specific part of the muscle and specific female pelvic floor problems (De Lancey et al. 2007). Knowing the type of injury is an important guide to proper treatment (De Lancey et al. 2007; Bo et al. 2005).

Static images show their morphology while dynamic images show the functional changes that occur on straining and contraction of the pelvic floor. MR images can contribute to generate 3D solids of pelvic floor muscles through manual segmentation.

To study the complex biomechanical behavior of the pelvic floor muscles, a computer model based on the finite element (FE) theory is necessary, because a relationship between the loading and muscle forces in three dimensions can be represented instead a simple representation of the muscle action by a one-dimensional muscle line of action (Janda et al. 2003).

The aim of this study is to calculate the area and its moment of inertia of female pelvic floor muscles by using manual segmentation technique. The methodology is applied to women with related pathologies such as urinary incontinence and prolapse.

2 MATERIALS AND METHODS

2.1 Construct a 3D model

Each model was built, from a set of MR images obtained in DICOM format and subsequently converted to jpeg format, with all the same image size. After the preparation of images to use, one can start the construction of the model, using CAD software. Thus it is created a set of parallel plans, separated according to the value at which the MR images were obtained. This study used twenty consecutive images obtained in the axial plane for each of the eight women. The MR images were acquired from the subject supine position, using a 3.0 T system. Field view of the exam was 25×25 cm, 2mm thick with no gap.

2.2 Sketches

The software inventor was used to manually draw the contour of the muscle pubovisceral and to build 3D reconstruction models. The models were made through splines in each sketch (Figure 1), documenting changes in the pubovisceral muscle, a part from the pelvic floor muscles, from the pubis (anterior compartment) to coccyx (posterior compartment). Then, a contour spline around the structure (in each sketch) that we want to study is modelled, to obtain the 3D model.

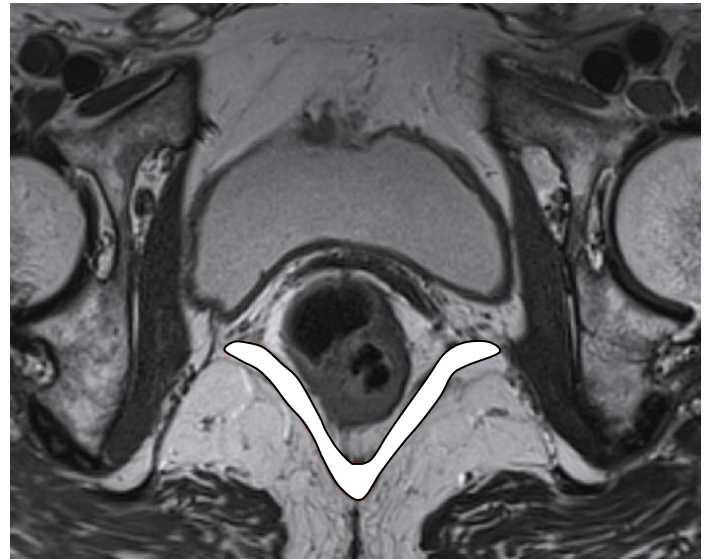


Figure 1. Contour of pubovisceral muscle on a slices.

Two sketches were chosen: sketch #2 (anterior) and #20 (closer to the posterior compartment), and biomechanics properties like area and stiffness (moment of inertia) were calculate for each sketch. In Figure 2 it is shown how the 3D model was constructed using splines on the contour of the pubovisceral muscle, using MRI images as background.

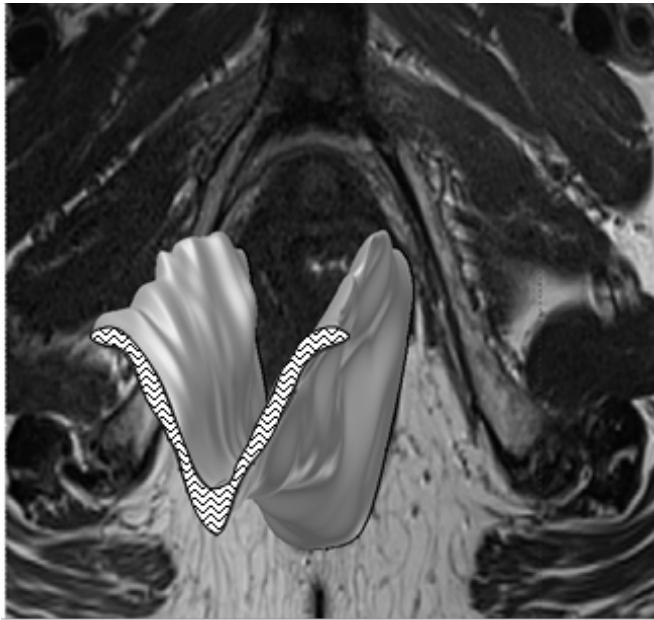


Figure 2. Construction of 3D model based on MR image.

3 RESULTS AND DISCUSSION

So far, efforts have concentrated on the levator ani muscle complex, because it is considered to be a critical structure in the maintenance of female pelvic floor support and continence (De Lancey, 1990 and Strohnehn et al. 1996).

Woman with prolapse are shown to have a 40% lower force generated during a pelvic muscle contraction than women without prolapse (De Lancey et al. 2007). When we find forces applied in a certain area it is important to calculate the moment of inertia, because, it can provide the amount of deformation being applied and its stability in a certain area. This difference in stability is accompanied by directions of the fibers that accompany the format area of each muscle structure.

As we can see in Figure 3 the moment of inertia of the pubovisceral muscle is much more higher in the cross section from sketch #2 (anterior) than in sketch #20 (posterior).

Figure 3. Moment of inertia for anterior and coccyx cross section.

A comparison between the area of the cross section in sketch #2 and #20 is presented in Figure.4. One can see the predominance of increased area in the sketches #2 when compared with #20.

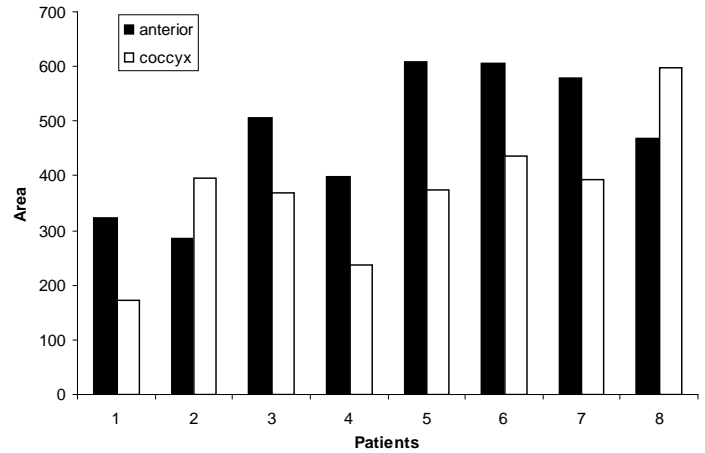


Figure 4. Area for anterior and coccyx cross section.

4 CONCLUSIONS

Higher values for the moment of inertia can be encountered in sketche 2. This conclusion can lead to more stability in the anterior compartment of pelvic floor visceral. This lack of stability in sketch 20 shows that this region presents more capacity to move when it is subjected to a complex system of forces. One may not that this conclusion can not be established if only the values of area are obtained.

ACKNOWLEDGEMENTS

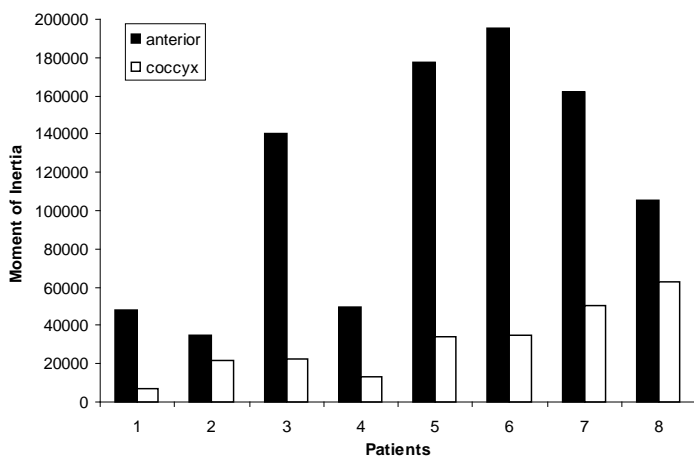
The authors truly acknowledge the funding provided by Ministério da Ciência, Tecnologia e Ensino Superior – Fundação para a Ciência e a Tecnologia (Portugal) and by FEDER, under grant PTDC/SAUBEB/71459/2006.

5 REFERENCES

Bergmann, G. Deuretzbacher, G. heller, M. Garicehn, F. Rohlmann, A. Strauss, J. et al. 2001. Hip forces and gait patterns from routine activities. *J Biomech* 34: 859-871.

Bo, K. 2004 Pelvic floor muscles training is effective in treatment of female strees urinary incontinence, but how does it work? *International Urogynecol Journal*, Olso, v.15: 76-84.

Bo, K.; Raastad, R.; Finckenhagen, H, B. 2005 Does the size of the vaginal probe affect measurement of pelvic floor muscle strength? *Acta Obstetricia et Gynecologica Scandinavica*, 84: 129-133.



- BO, K.; Sherburn, M. 2005, Evaluation of female pelvic floor muscle function and strength. *Physical Therapy, Norway*, 85; 3:269-282.
- Bump, R.C 1991 Assessment of Kegel pelvic muscle exercises performance after brief verbal instruction *Am J of Obst Gyn*, 165:2,322-328.
- De Lancey J O L, Morgan D M, Fenner D E, Kearney R, Guire K, Miller J M, Hsu HH, Umek W, Ashton-Miller J A. 2007. Comparison of Levator Ani Muscle Defects and Function in Women With and Without Pelvic Organ Prolapse. *Obstetrics & Gynecology*, v.109, (2), 295-302,
- Ghoniem G. Stanford E. Kenton K. Ahtari C. Goldberg R. Mascarenhas T. Parekh M. Tamussino K. Tossou S. Lose G. Petri E. 2008. *Evaluation and outcome measures in the treatment of female urinary stress incontinence: International Urogynecological Association, IUGA*, *Int Urogynecol J Pelvic Floor Dysfunct* 19:5-33.
- Hagen S. Stark D. Sinclair L. Glazener C. Ramsay I. 2006. A feasibility study for a randomized controlled trial of pelvic floor muscle training intervention for women with pelvic organ prolapse. *Neurounol Urodyn* 25:532-533.
- Hunskar S. Lose G. Voss S. 2004. The prevalence of urinary incontinence in women in four European countries. *BJU Int* 93:324-330.
- Janda, S. Van der Helm, F.C.T. Blok, S.B. 2003. Measuring morphological parameters of the pelvic floor for finite elements modeling purpose. *J Biomech*, 36: 749-757.
- J. Stoker, SA. Taylor, JOL. DeLancey, *Imaging Pelvic Floor Disorders*. 2th ed. Berlin Heidelberg, Germany: Springer-Verlag; 2008.
- Olsen A.L. Smith V.J. Bergstrom J.O. Colling J.C. Clark A.L. 1997. Epidemiology of surgically managed pelvic organ prolapse and urinary incontinence. *Obstet Gynecol* 89:501.
- Petricelli C.D.A., 2003 A importância dos exercícios perineais na saúde e sexualidade feminina, *Fisio e Terapia* Ano VII, 24-25.
- Piya-Anant M. Therasakvichya S, Leelaphatanadit C. Techatri-sak K. 2003. Integrated health research program for the Thai elderly: prevalence of genital prolapse and effectiveness of pelvic floor exercise to prevent worsening of genital prolapse in elderly women. *J Med Assoc Thai* 86:509-515.
- Reis, AB; Barrote, D, Baracho, ELS, Neto, JM 2002, Anatomia feminina. In: BARACHO, E.L.S. Fisioterapia Aplicada a Obstetrícia – Aspectos de Ginecologia e Neonatologia. 3ª ed. Rio de Janeiro: Medsi, , cap. 1:1-18.
- Subak L.L. Waetjen L.E. Van Den Eeden S. Thom D.H. Vittinghoff E. Brown J.S. 2001. Cost of pelvic organ prolapse surgery in the United States. *Obstet Gynecol* 98:646-651.