

An Automatic Method for Assessing Retinal Vessel Width Changes

Behdad Dashtbozorg^{1,2}
behdad.dashtbozorg@fe.up.pt

Ana Maria Mendonça^{1,2}
amendon@fe.up.pt

Aurélio Campilho^{1,2}
campilho@fe.up.pt

¹ INEB-Instituto de Engenharia Biomédica,
Porto, Portugal

² Faculdade de Engenharia,
Universidade do Porto,
Rua Dr. Roberto Frias, 4200-465 Porto, Portugal

Abstract

The Arteriolar-to-Venular Ratio (AVR) is commonly used in studies for the diagnosis of diseases such as diabetes, hypertension or cardio-vascular pathologies. This paper presents an automatic approach for the estimation of the Arteriolar-to-Venular Ratio (AVR) in retinal images. The proposed method includes vessel segmentation, vessel caliber estimation, optic disc detection, region of interest determination, artery/vein classification and AVR calculation. The method was assessed using the images of the INSPIRE-AVR database. A mean error of 0.05 was obtained when the method's results were compared with reference AVR values provided with this dataset, thus demonstrating the adequacy of the proposed solution for AVR estimation.

1 Introduction

Retinal vessel features play an important role in the early diagnosis of several systemic diseases, namely diabetes, hypertension and vascular disorders. In diabetic retinopathy, the blood vessels often show abnormalities at early stages [8]. Changes in retinal blood vessels, such as significant dilatation and elongation of main arteries, veins, and their branches, are also frequently associated with hypertension and other cardio-vascular pathologies [2], [7].

Among several characteristic signs associated with retinal vascular changes, the Arteriolar-to-Venular Ratio (AVR) is used as an indicator of cardiovascular risk since it can reflect the narrowing of the retinal blood vessels. A low AVR value is associated with a high blood pressure, thus increasing the risk of stroke, diabetes and hypertension. Development of an automatic image analysis system for the estimation of AVR values requires vessel segmentation, accurate vessel caliber measurement, optic disc detection for region of interest delineation and artery/vein classification [3]. In this paper, we propose a fully automatic method for the estimation of the AVR value which achieves better performance than recently proposed approaches.

2 Material and methods

The estimation of AVR requires optic disc detection, vessel segmentation, accurate vessel caliber measurement and artery/vein classification [3]. Vessel segmentation must be used for finding the vessels, and optic disc detection is necessary to locate the region of interest (ROI) where vessel calibers are measured. An automatic AVR measurement system must classify the retinal vessels into arteries and veins with high accuracy since small classification errors can have a significant influence on AVR values. Finally, caliber measurements are used to compute AVR, according to the formula proposed by Knudtson *et al.* [3]. Figure 1 depicts the block diagram of the proposed method for AVR estimation. The main phases of the proposed method are described in the following subsections.

2.1 Vessel segmentation

For segmenting the retinal vessels, the method previously proposed by Mendonça *et al.* [5] was chosen and adapted for the segmentation of high resolution images [6]. Figure 2(b) illustrates the vascular tree for the original image of Figure 2(a).

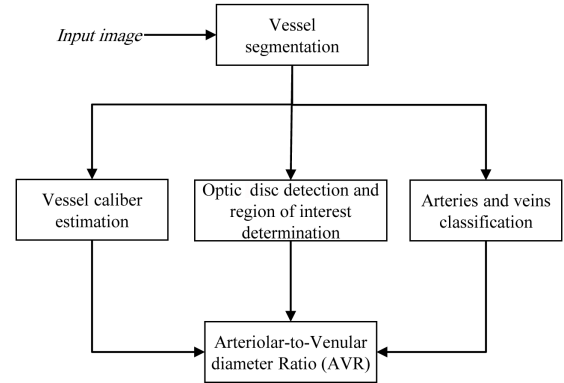


Figure 1: Block diagram of the proposed method for AVR estimation.

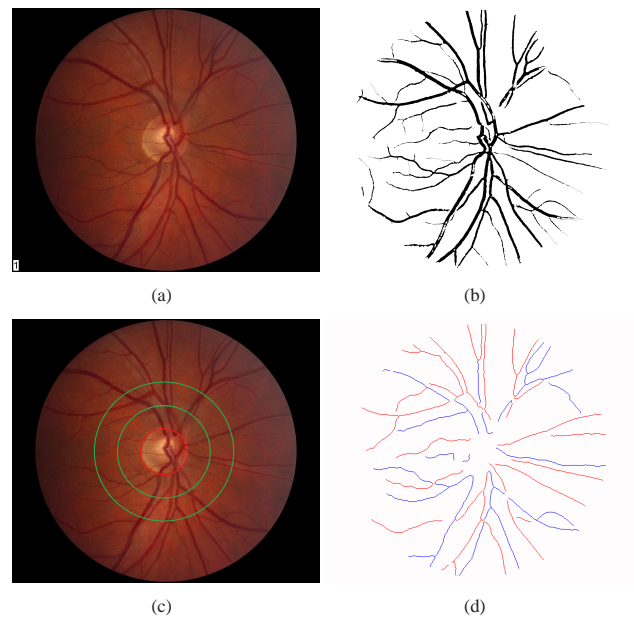


Figure 2: (a) Original image; (b) Vessel segmentation result; (c) Region of interest for AVR (delimited by the two green circles) and the optic disc margin (red circle); (d) A/V classification result.

2.2 Vessel caliber measurement

For vessel caliber measurement a distance transform is applied to the segmented vascular tree and the result of this transform in each vessel pixel is the distance of the pixel to the closest boundary point, d . After that, for each vessel centerline pixel, the vessel caliber value, vc , is estimated by $vc = 2d - 1$.

2.3 Region of interest detection

The optic disc center (ODC) is located using an automatic methodology proposed by Mendonça *et al.* which is based on the entropy of vascular directions [4]; the region of interest (ROI) is centered on the ODC, and defined considering a disc diameter adapted to image resolution. Figure 2(c) shows an example of optic disc boundary and the region of interest for calculating the AVR.

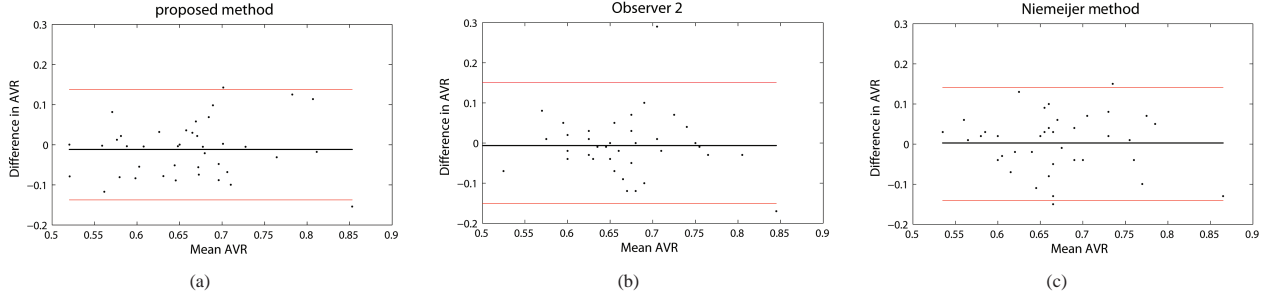


Figure 3: Bland-Altman plots of the agreement: (a) between proposed method and reference; (b) between Observer 2 and reference; (c) between Niemeijer’s method and reference.

2.4 Artery/vein classification

In order to classify the vessels as an artery or as a vein, an improved version of the automatic graph-based A/V classification method previously described in [1] is used. This method represents the segmented vasculature as a graph, which is afterwards modified for removing some typical errors and misrepresentations. Then the modified graph is analyzed for deciding about the type of intersection points (graph nodes) and based on the node types in each separate subgraph, all vessel segments (graph links) that belong to a particular vessel are identified and labeled using two distinct labels. Finally, intensity features are measured from the segments for assigning the final artery/vein class to each label. The result of A/V classification is shown in Figure2(d).

2.5 AVR calculation

We have followed Knudtson’s revised formula [3] to calculate the AVR value. The Knudtson’s formulas for approximating the vessel equivalents are as the following:

$$\text{Arterioles} : \hat{W}_a = 0.88 * \left(w_{a1}^2 + w_{a2}^2 \right)^{\frac{1}{2}} \quad (1)$$

$$\text{Venules} : \hat{W}_v = 0.95 * \left(w_{v1}^2 + w_{v2}^2 \right)^{\frac{1}{2}} \quad (2)$$

where w_{a1} , w_{a2} , and \hat{W}_a are, respectively, the widths of the narrower branch, the wider branch, and the estimate of parent trunk for arteries. w_{v1} , w_{v2} , and \hat{W}_v have the same meanings for veins. For computing the central retinal artery equivalent, a set with the six largest arteries is first selected. Then, an algorithm is used for pairing up the largest and the smallest vessels in this set, and the parent trunk width is determined using Knudtson’s formula (1). A new set is formed by substituting the largest and smallest arteries with the parent trunk, and this algorithm is iterated until a single vessel is kept, whose width is the CRAE value. A similar procedure is used for calculating the CRVE, starting from the set formed by the six largest veins and using Knudtson’s formula (2). An approach similar to the one described in [9] is applied for AVR measurement. The ROI is equidistantly sampled to provide six regions. For each region, the six largest arteries and the six largest veins are identified, and the regional AVR value is obtained. The final AVR estimate for the complete image is the average of the six regional values.

Table 1: Comparison of AVR values

	Reference	Proposed method		Observer 2		Niemeijer’s method	
	AVR	AVR	error	AVR	error	AVR	error
Mean	0.67	0.65	0.05	0.66	0.05	0.67	0.06
Stdev	0.08	0.09	0.04	0.08	0.05	0.07	0.04
Min	0.52	0.48	0	0.45	0	0.55	0.01
Max	0.93	0.86	0.15	0.85	0.29	0.81	0.15

3 Results

For validating the proposed AVR estimation method, we have used the 40 images of the INSPIRE-AVR dataset. This dataset includes two AVR measures that were computed by two ophthalmologists using a semi-automated computer program. The AVR estimates for Observer 1 are used as reference for calculating the errors for the results of both Observer 2 and our method. The analysis of the mean AVR and error values in Table 1 allow the conclusion that the error of our method is similar to the one of

Observer 2 and is smaller than the error of the recent approach presented by Niemeijer *et al.* [9]. The agreement between the different methods and the reference can be observed in the Bland-Altman plots depicted in Figure 3. From the observation of these plots, it is worth mentioning that the results of our method are similar to those of Observer 2, and do not show a substantial bias as the mean of differences between the AVR values is close to 0. The 95% limits of agreement for all methods are also almost identical.

4 Conclusions

We have described an automatic method for calculating the AVR value in retinal images that is supported by a new solution for A/V vessel classification. The herein proposed approach was assessed in the images of the INSPIRE-AVR dataset where it has achieved a mean error of 0.05, identical to the one obtained by Observer 2. The low error is promising and demonstrates that our solution has a high potential for clinical application.

In order to determine the ROI for AVR calculation, a constant value is assumed for the optic disc diameter in all images. Therefore, as future work, we will focus on the development of a new approach for optic disc boundary detection and diameter measurement.

References

- [1] B. Dashtbozorg, A.M. Mendonça, and A. Campilho. Automatic classification of retinal vessels using structural and intensity information. *Pattern Recognition and Image Analysis, LNCS*, vol. 7887:600–607, 2013.
- [2] Kit Guan, Chris Hudson, Tien Wong, Mila Kisilevsky, Ravi K. Nrusimhadevara, Wai Ching Lam, Mark Mandelcorn, Robert G. Devenyi, and John G. Flanagan. Retinal hemodynamics in early diabetic macular edema. *Diabetes*, 55:813–818, 2006.
- [3] M. D. Knudtson, K. E. Lee, L. D. Hubbard, T. Y. Wong, R. Klein, and B. E. K. Klein. Revised formulas for summarizing retinal vessel diameters. *Current eye research*, vol. 27:143–9, 2003.
- [4] A. Mendonça, F. Cardoso, A. Sousa, and A. Campilho. Automatic localization of the optic disc in retinal images based on the entropy of vascular directions. *Image Analysis and Recognition, LNCS*, vol. 7325:424–431, 2012.
- [5] A.M. Mendonça and A. Campilho. Segmentation of retinal blood vessels by combining the detection of centerlines and morphological reconstruction. *IEEE Trans. Med. Imag.*, vol. 25:1200–13, 2006.
- [6] A.M. Mendonça, B. Dashtbozorg, and A. Campilho. Segmentation of the vascular network of the retina. In E. Y. K. Ng, U. Rajendra Acharya, Jasjit S. Suri, and Aurelio Campilho, editors, *Image Analysis and Modeling in Ophthalmology*. CRC Press, 2013.
- [7] A. S. Neubauer, M. Ludtke, C. Haritoglou, S. Priglinger, and A. Kampik. Retinal vessel analysis reproducibility in assessing cardiovascular disease. *Optometry and Vision Science*, 85:247–254, 2008.
- [8] T. T. Nguyen and T. Y. Wong. Retinal vascular changes and diabetic retinopathy. *Current Diabetes Reports*, 9:277–283, 2009.
- [9] M. Niemeijer, X. Xu, A. Dumitrescu, P. Gupta P, and M. Abr  moff B. van Ginneken, J. Folk. Automated measurement of the arteriolar-to-venular width ratio in digital color fundus photographs. *IEEE Trans. Med. Imag.*, vol. 30:1941–1950, 2011.