

## Preprocessing of Magnetic Resonance Images with Multiple Sclerosis Lesions

Rafaela Pinto<sup>1</sup>, Sandra Ventura<sup>2</sup>, Vítor Silva<sup>3</sup>, João Manuel R.S. Tavares<sup>4</sup>

<sup>1</sup>MSc Student Engenharia Biomédica, Faculdade de Engenharia, Universidade do Porto, Portugal

<sup>2</sup>Departamento Radiologia, Escola Superior de Tecnologia da Saúde do Porto, Instituto Politécnico do Porto, Portugal

<sup>3</sup> Serviço de Radiologia do Centro Hospitalar de S. João, Escola Superior de Tecnologia da Saúde do Porto, Instituto Politécnico do Porto, Portugal

<sup>4</sup> Instituto de Ciência e Inovação em Engenharia Mecânica e Engenharia Industrial, Faculdade de Engenharia, Universidade do Porto, Portugal  
[up201508342@fe.up.pt](mailto:up201508342@fe.up.pt)

### INTRODUCTION

According to the World Health Organization, it is estimated that multiple sclerosis (MS) affects around 2.5 million people worldwide and more than 5000 in Portugal<sup>1</sup>.

Multiple sclerosis is an inflammatory, demyelinating, idiopathic, and often disabling central nervous system disease that affects the white matter diagnosed in young adults and predominantly affects women<sup>2</sup>.

Multiple sclerosis is the most common neurological disorder with unexplained causes and major repercussions in the lives of patients, causing the active search for answers by the researchers. Although the disease cannot be cured or prevented at this time, the available treatments only reduce its severity and delay its progression<sup>2</sup>. In recent years, there has been a major development of image processing and analysis techniques in order to facilitate early diagnosis and suitable treatment. In general, images acquired by imaging devices and specialized techniques require transformations and enhancements to make them more suitable in order to extract as much information as desired with greater efficiency.

Several authors, as in<sup>3,4,5</sup>, have described techniques of image preprocessing and segmentation of MS lesions, making evident the advantages of such computational tools. In this work, different preprocessing algorithms were applied in order to perform the brain extraction from resonance magnetic (RM) images for their easier further analysis.

### EXPERIMENTAL METHODS

In the experimental work, the data provided by the *Longitudinal Multiple Sclerosis Challenge 2015*, composed of 5 training images and 14 test images in different ponderations, was used; mainly, the central sections of the FLAIR sequence. In the preprocessing of the images, multiple operations were performed, including: image smoothing and noise reduction, brain extraction, correction and intensity normalization. In order to smooth and remove image noise, the average, median, *Gaussian*, *Perona & Malik's* and *Wiener* filters were applied with different parameters. For brain extraction, automatic algorithms were used: BSE, BET and SPECTRE algorithms included in the MIPAV software were compared against a semi-automatic algorithm and the manual delineations (M1 and M2) obtained by two experts. It was also developed and compared a new automatic approach for the extraction of brain structures based on morphological operations. Finally, the gamma correction algorithm was applied in order to adjust the brightness of each image and the normalization of the images was performed.

### RESULTS AND DISCUSSION

In order to evaluate the used smoothing and noise reduction filters, quality metrics were used: structural similarity index (SSIM), signal-to-noise ratio (SNR), peak signal-to-noise ratio (PSNR), visual information of fidelity (VIF), universal quality index (UQI) and absolute mean error (MAE). It was found that *Perona & Malik's* filter obtained the best results, with the lowest MAE and the highest PSNR and consequently the highest SNR. Through the application of this filter, it was verified that the brain structures and the edges were more clearly preserved, which was confirmed by the obtained SSIM values. The *Wiener* filter proved to be the second best smoothing filter, and the average filter the one that led to the worst results.

Figure 1 shows the manual delimitations, and the results of the semi-automatic, BET, BSE, SPECTRE and proposed algorithms. These algorithms were compared statistically relatively to the manual delimitations

based on the SSIM, MAE, SNR and PSNR metrics, and also based on the Dice coefficient and processing time.

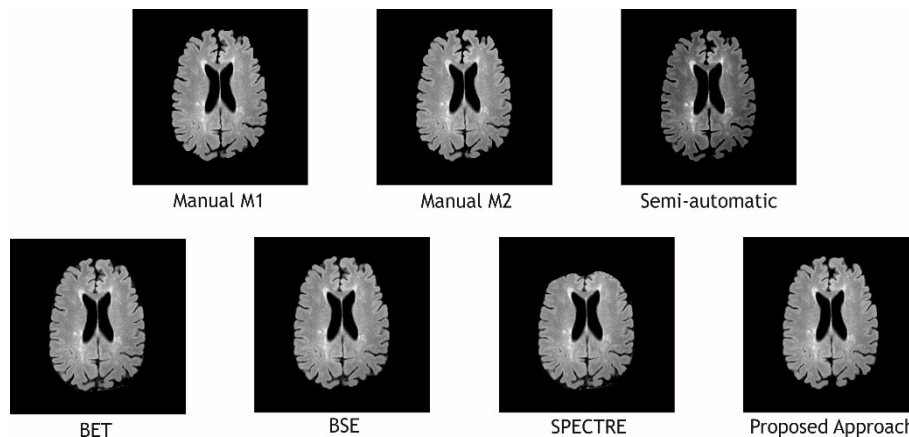


Figure 1 – Manual results and the one obtained by the used brain extraction algorithms.

It was observed that the automatic algorithms were most effective than the semi-automatic algorithm, except the SPECTRE algorithm that presented a smaller similarity with the manual segmentations, and the BSE algorithm that presented similar results. However, the SPECTRE algorithm had lower MAE. It was verified that the BET and proposed algorithms obtained the best results. As for the processing time, the proposed, BSE and BET algorithms were the faster ones, standing out from the remainder ones with times of 9, 11 and 20 s, respectively. The gamma correction step and the normalization proved to be very important in order to the lesions be easy identified in the input images.

## CONCLUSION

Through the application of smoothing and noise reduction filters, it is observed that *Perona & Malik's* filter is the one that provided the best results and the most suitable for the database under study, as evidenced by the results obtained as to the used quality metrics. It could be concluded that the algorithm developed to remove the skull was the one that led to the best results, as was evidenced by the highest structural similarity index ( $0.959 \pm 0.015$ ) and Dice coefficient ( $0.952 \pm 0.011$ ) and low mean absolute error ( $0.891 \pm 0.625$ ). These metric values refer to the average value of all images in the database and the respective standard deviation. The normalization of the intensity of the images was very important due to the fact that the images had different intensity ranges which complicates the efficient detection of the lesions.

Through this study, it was verified that the image preprocessing techniques are fundamental to obtain good results in the subsequent stages; namely, in the segmentation step.

## ACKNOWLEDGMENTS

Authors gratefully acknowledge the funding of Project NORTE-01-0145-FEDER-000022 - SciTech - Science and Technology for Competitive and Sustainable Industries, co-financed by "Programa Operacional Regional do Norte" (NORTE2020), through "Fundo Europeu de Desenvolvimento Regional" (FEDER).

## REFERENCES

1. Dua T., Rompani P., Atlas: Multiple Sclerosis Resources in the World 2008, World Health Organization, 2008
2. Compston A., Coles A., Multiple Sclerosis, *The Lancet* 359:1221-1231, 2002
3. Lladó X. *et al.*, Segmentation of multiple sclerosis lesions in brain MRI: A review of automated approaches, *Information Sciences* 186:164-185, 2012
4. García-Lorenzo D., *et al.*, Review of automatic segmentation methods of multiple sclerosis white matter lesions on conventional magnetic resonance imaging, *Medical Image Analysis* 17:1-18, 2013
5. Cabezas M. *et al.*, Automatic multiple sclerosis lesion detection in brain MRI by FLAIR thresholding, *Computer Methods and Programs in Biomedicine* 115:147-161, 2014