

Extended Abstract: PET-MRI in Neuroimaging: technique role in Alzheimer Disease

Domingos Vieira
*Instituto de Ciência e Inovação
em Engenharia Mecânica e
Engenharia Industrial,
Faculdade de Engenharia,
Universidade do Porto
mim09007@med.up.pt*

Ricardo Vardasca
*Instituto de Ciência e Inovação
em Engenharia Mecânica e
Engenharia Industrial,
Faculdade de Engenharia,
Universidade do Porto
ricardo.vardasca@fe.up.pt*

João Manuel R. S. Tavares
*Instituto de Ciência e Inovação
em Engenharia Mecânica e
Engenharia Industrial,
Faculdade de Engenharia,
Universidade do Porto
tavares@fe.up.pt*

Abstract - Hybrid or multimodal imaging has provided excellent opportunities to meet the needs inherent in the management of neurodegenerative diseases, especially in Alzheimer Disease context. PET-MRI equipment for simultaneous data acquisition attempts to address this challenge by bridging the limitations of PET-CT at the brain level and improving the results achieved through a simultaneous real-time combination of quantitative neurophysiological information from PET and accurate MRI morphological information, with greater radiological safety. Therefore, the PET-MRI technique presents high potential for diagnostic and follow-up studies. The aim of this review was to compile the main advantages related with PET-MRI along with the detection of the main challenges which remain to be resolved for a full clinical validation of the technique in Neuroimaging field are identified.

Index Terms – Alzheimer disease, Neurodegenerative disease, Neuroimaging and PET-MRI

INTRODUCTION

Alzheimer's disease (AD) constitutes one of the most common neurodegenerative diseases today, with about 35 million people worldwide being affected by this disease. It presents a progressive loss of associated memory and a significant weakening of cognitive functions with profound impact in clinical, social and economical areas. The pathogenesis of this type of disease is complex and still lacks a complete knowledge of its origin, development and remission. An early diagnosis and intervention is essential to control the development of disease.

Not along ago, hybrid or multimodal imaging has provided excellent opportunities to meet the needs inherent in the management of Central Nervous System (CNS) diseases, especially regarding neurodegenerative diseases.

Positron Emission Tomography-Computerized Tomography (PET-CT) has been successfully applied in clinical practice with better results when compared to the PET or CT alone options. However, the ability of Magnetic Resonance Imaging (MRI) to obtain higher spatial resolution levels notably in soft tissues (a particularly critical factor in the context of the brain region) as well as the non-use of radiation made evident the need to add this technique as a new component to be included in a multimodality solution. PET-MRI equipment for simultaneous data acquisition attempts to address this challenge by bridging the limitations of PET-CT at the brain region and improving the results achieved through a real-time combination of PET quantitative neurophysiological information and MRI morphological information, with greater radiological safety. Due to these facts, the PET-MRI technique presents high potential for brain studies, although there are challenges yet to be addressed.

The aim of this research is to describe, compile and review the existing scientific and technical contents in the literature about the application of the hybrid PET-MRI technique in Neuroimaging, more precisely in the context of AD.

METHODOLOGY

A literature review was performed, following a PICO methodology with the question: *"What is the role of PET-MRI technique in the diagnosis of neurodegenerative diseases, specifically in context of Alzheimer's disease?"*.

Based on the formulated question, key words and key phrases were identified for scientific database research: "Alzheimer", "neurodegenerative disease" "brain" and "PET-MRI" (in the different acronyms normally identified with Hybrid technique). The SCOPUSTM platform was used as digital repository of research.

Only publications cataloged by the database as "article review" and published since 2010 in English language until February 2016 were considered.

With the set of publications obtained, their feasibility was verified based on the application of the following exclusion criteria: possibility of access to the full version of the publications; verification of redundant items; empirical analysis of abstracts based on their relevance to the research question (publications concerning other body areas other than the brain region, relating in particular to unique and non-hybrid imaging modalities and research or preclinical publications were rejected).

RESULTS

Based on the methodology and the inclusion criteria used, a total of 60 publications were initially obtained, which after applying the exclusion criteria dropped to a final number of 41 scientific publications. The results obtained can be stratified into five fields of interest.

I. PET-MRI EQUIPMENTS - DESIGN AND COMPONENTS

At present, there are four options of PET-MRI equipment available in the market, and the main performance parameters can be observed and compared in Table 1 [1].

II. ATTENUATION CORRECTION IN PET-MRI

A technical challenge in hybrid imaging PET-MRI is the attenuation correction (AC) of PET emission images based on MRI data. Correction necessary for accurate quantification of radiotracer concentration.

In PET-MRI imaging, AC of PET data needs to be performed through MRI data, which is based on proton density and tissue relaxation properties as opposed to CT information that is based on x-ray attenuation in tissues [2,3].

To this end, different methodologies may be applied namely the Dixon methodology or the T1-weighted MRI sequence of ecogradient. These rapid MRI sequence methods are based on measurements of proton density and relaxation times (T1 and T2) of specific tissues, parameters that are not directly convertible into PET coefficients of 511 keV energy levels. Typically, MRI images are initially segmented into different classes based on tissue types, and later predefined linear attenuation coefficients are calculated for the computation of the attenuation maps necessary for the correction of PET images during data reconstruction.

Nowadays, in brain imaging with PET-MRI, a huge challenge is related to the rapid transverse relaxation of the MRI signal. The AC of PET images requires density maps of the object under study from morphological information of MRI; however, tissues with a higher density as the case of the bone tissue are difficult to detect in MRI due to their short relaxation periods. MRI techniques, which allow

detection of rapid decay of signal become essential for detection of specific tissues, especially bone tissue. A low proton density such as that present in bone tissue implies difficulties in visualizing structures and contrast with adjacent structures such as surrounding soft tissues and background [1-4].

TABLE 1. PERFORMANCE CHARACTERISTICS OF PET-MRI EQUIPMENT AVAILABLE IN THE MARKET TODAY (NEMA NU-2 2007) [1]

PET Characteristic s and NEMA NU-2 Performances	Philips Ingenuit y PET/MR	GE PET/CT Discovery 690 (in Trimodalit y Setup)	GE Signa PET/M R	Siemens Biograp h mMR
PET FOV axial	18	15.7	25	25.8
PET FOV transaxial	57.6	50-70	60	59.4
MRI or CT FOV transaxial (for attenuation)	45	CT	50	50
Average spatial resolution at 1 cm off center (mm FWHM)	4.7	4.7	4.2	4.3
Average Spatial resolution at 10 cm off center (mm FWHM)	5.1	5.3	5.1	5.5
Timing Resolution (ps)	525	544	385	2930
Energy Resolution (FWHM %)	12	12.4	10.3	11.5
Sensitivity (average 0 and 10 cm) (cps/kBq)	7.1	7.5	22.9	14.4
Max NECR (kcps) at (kBq/mL)	88.5 at 13.7	139.1 at 29.0	218 at 17.7	184 at 23.1
Scatter fraction at NECR peak (%)	26	37	43.6	37.9

FWHM, full width at half maximum; NECR, noise equivalent count rate; NEMA, National Electrical Manufacturers Association

In a more efficient approach, the application of frequency coding in a radial three-dimensional (3D) centrifugal scheme may be a solution. *Ultrashort Echo Time* (UTE) and *Zero Echo Time* (ZTE) sequences in MRI acquisition have been reported as a possible solution for the visualization of bone tissue with very short T2 images, thus allowing AC to be at the bone level during image segmentation. This may possibly be enhanced by the combination of sequences obtained by the Dixon technique, obtaining AC maps like maps obtained with CT acquisition of CT in a PET-CT equipment. This method presents some disadvantages such as the long data acquisition times and the limitation of efficacy to larger field of views (FOVs), although in cerebral context this parameter is not so critical. [1-4].

All of these methods have advantages and disadvantages, and for this reason still there is not a consensus solution. The difficulty in segmentation of bone tissue is currently one of the main lines of investigation to solve the problem of AC in PET-MRI, particularly in the cerebral context due to the greater bone density in this region [5-9].

III. IMAGE DATA RECONSTRUCTION

PET-MRI imaging reconstruction options available are identical to those used for PET-CT. Thus, reconstruction algorithms are based on iterative reconstruction methods and require data for normalization procedures, dead time analysis, photonic decay, AC and scattering correction for treatment of functional PET images, as required within the scope of PET-CT. An important factor to highlight is the possibility of PET-TOF image acquisition, since it allows for improved AC and scattering correction through calculating the difference of photonic detection in PET, the location of the origin of the events is more accurate along of the typical PET line of response (LOR). Recent studies (Vandenberghe *et al.*, 2016) have identified PET-TOF acquisition applied in PET-MRI data acquisition technique as a solution to perform a simultaneous reconstruction of the functional and morphological data and thus solve the important correction problems, although this solution needs validation in clinical scope [10-12].

IV. PET-MRI IN CLINICAL NEUROIMAGING

Given the advantageous characteristics of the MRI morphological technique and the PET physiological technique, it was quickly found necessary to correlate the two types of information to unite the best of the two imaging fields. The emergence of the hybrid PET-MRI equipment through simultaneous data acquisition of the brain region allowed an improvement in the co-registration and alignment of data, which already evident when using fusion techniques, but above all an enhancement of the results in terms of interconnection intrinsic diagnosis between the information provided by different PET radiopharmaceuticals and high contrast of brain tissues provided by the diversity of MRI techniques [13-21].

One of the inherent advantages of the PET technique and its associated biodistribution principle is the wide variety of specific radiopharmaceuticals to a given pathology. The main PET targets currently available in clinical practice can be seen in Table 2. The major PET radiopharmaceutical used in neurodegenerative diseases is ^{18}F -FDG which represents a universal neuronal and synaptic integrity biomarker due to its proportional correlation with the variations of glycolytic need of brain tissue; i.e., greater metabolic avidity tends to accumulate sugary compounds. In the case of AD, the lower uptake of this radiopharmaceutical in bilateral temporoparietal areas due to reduced accumulation of the tracer makes it necessary to use other options. Currently a few more PET

radiopharmaceuticals appear in the context of AD intracellular plaques Beta Amyloid deposits: ^{18}F -Florbetapir, ^{18}F -Florbetaben or ^{18}F -Flutemetamol [14,22-25].

All these indicators are strongly related to the pathology and the knowledge of their mode of relationship and their mechanisms of action is fundamental for the diagnosis and prognosis of AD in differentiation from other types of dementias [14-23].

The MRI technique is presented as the gold standard technique in the evaluation of neurodegenerative situations. The different techniques associated with this imaging method contribute significantly to this fact. In Table 2, the MRI techniques usually applied in clinical practice in the context of neurodegenerative diseases can be identified [14-23].

In the context of AD, data acquisition in T2-FLAIR (*fluid-attenuated inversion*) and/or T1 3D GRE images (*gradient echo*) can identify patterns of temporal atrophy per a given score - the so-called *Scheltens score* [14-23].

TABLE 2. CURRENT PET TARGETS AND MRI SEQUENCES FOR NEURODEGENERATIVE DISEASES IMAGING [14].

Disease	Typical PET Targets	Typical MRI Sequences
Alzheimer disease	Amyloid plaques and glucose consumption	T2 FLAIR and T1 3D GRE
FTLD	Glucose consumption	FLAIR and T1 3D GRE
Vascular dementia	Glucose consumption	FLAIR, T2*/SWI and DWI
DLB	Glucose consumption	FLAIR and T1 3D GRE
Parkinson disease	Dopamine synthesis	T1, T2 multiplanar and T2*/SWI
Atypical parkinsonian syndromes	Glucose consumption	T1, T2 multiplanar and T2*/SWI
Huntington disease	Glucose consumption	T1, T2 and T2*/SWI
ALS	Glucose consumption	T1 and T2
CJD	Glucose consumption	DWI, FLAIR, T1 and T2

3D, three-dimensional; CJD, Creutzfeldt-Jakob disease; DLB, dementia with lewy bodies; DWI, diffusion-weighted imaging; FLAIR, fluid-attenuated inversion recovery; GRE, gradient echo; SWI, susceptibility-weighted imaging

Together, these techniques essentially provide support and consistent information to clinical results and non-imaging biomarkers, as well as to exclude other neurodegenerative pathologies with similar clinical symptoms and indications (Figure 1) [14-23].

V. PET-MRI exam Protocols

Unlike the usual protocols and flow of procedures in image acquisition with other hybrid techniques, as in the case of PET-CT, in PET-MRI protocols there are difficulties in the organization and management of the various moments of data acquisition mainly due to the unlimited number of MRI pulse sequences techniques, which lead to a high number of possible protocols to be adopted. However, it is necessary to reduce the options to

achieve standardized procedures, not only to make possible data acquisition clinically relevant and comfortably for patients, but also to compare results between studies. Designing a sequential schedule of events at appropriate time periods is equally critical for the PET-MRI hybrid technique to become economically viable in a cost-effective value context [24-28].

In the search for this solution, it is pointed out that, firstly, the choice of the ideal protocol depends on the type of existing PET-MRI equipment, since commercially there are options that provide the ability to simultaneous image acquisition in the same equipment, rather other options imply separate sequential acquisition of the two types of modalities through patient movement systems between different equipment [24-28].

Further, the clinical area of the study to be triggered also implies changes in protocols. In terms of PET-MRI application in neuroimaging, the choice of protocol and flow of procedures is more facilitated than in other fields

of interest; for example, in PET-MRI whole body studies [24-28].

One of the improvements adjacent to PET-MRI technique is the possibility of evaluating three types of information simultaneously in a shorter time interval: functional metabolic information of PET, morphological information and functional information of the MRI - the so-called Three-Eye Vision [6].

Brain PET-MRI is considered a specific imaging study in a limited FOV (only use of a bed position) with image acquisition times between 15 and 60 minutes per clinical indication, radiopharmaceutical applied and type of PET acquisition protocol (static or dynamic). Radiopharmaceuticals based on ^{18}F usually have acquisition times of 30 minutes. These shorter temporal windows lead to the identification of PET-MRI as a potential future gold standard imaging tool in the context of AD [24,25,29].

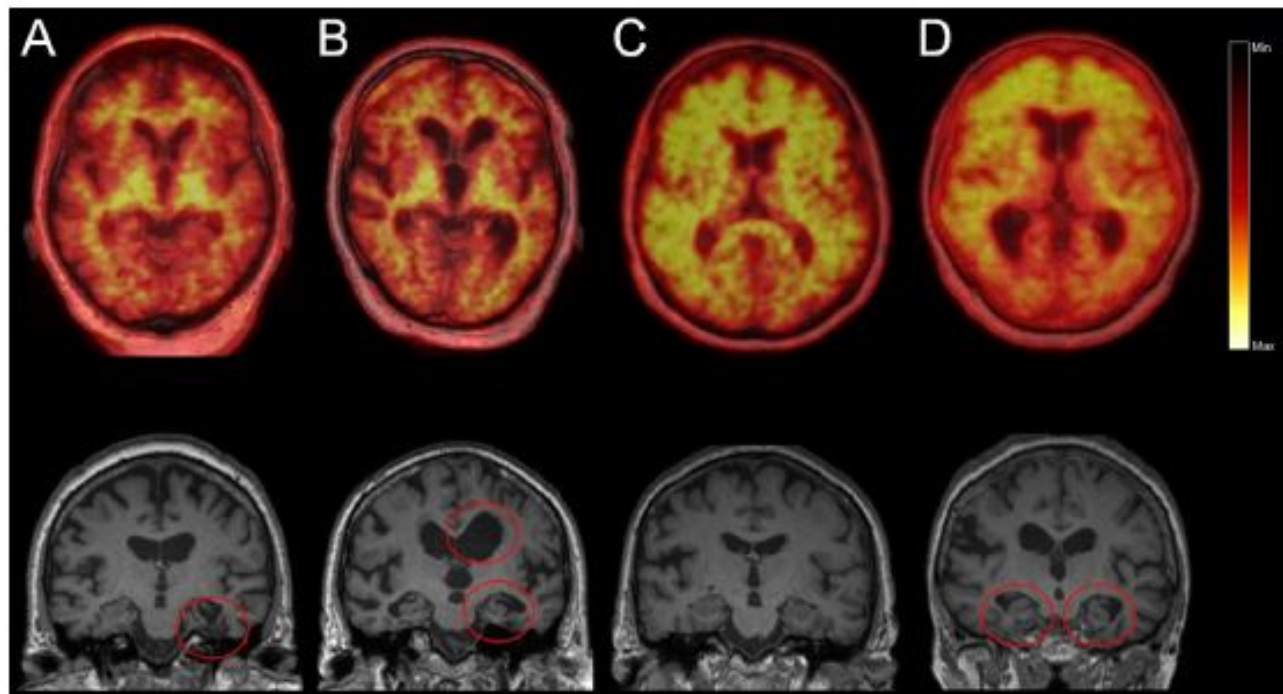


FIGURE 1 - DIFFERENT IMAGIOLOGICAL PATTERNS IN PATIENTS WITH LOW COGNITIVE DEFICIENCY THROUGH PET-MRI STUDIES WITH APPLICATION OF ^{18}F -FLORBETABEN, THE TOP LINE PRESENTS TRANSAXIAL PET-MRI IMAGES AND THE LOWER LINE CORONAL SECTIONS OF T1 IMAGES: (A) NEGATIVE PET STUDY, ILLNESS WITH TRAUMATIC CHANGES IN THE LEFT HYPOCAMP (CIRCLE) POSSIBLE INDICATION OF COGNITIVE DEFICIENCY; (B) NEGATIVE PET STUDY WITH HYPOCAMP ATROPHY (CIRCLES) AND SUBCORTICAL ASYMMETRY OF FRONTOTEMPORAL DEMENTIA; (C) PET POSITIVE STUDY, PATIENT WITH NO ATROPHY VISIBLE ON MRI IMAGE WITH POSSIBLE INTERMEDIATE AD LEVEL; AND (D) POSITIVE, PATIENT PET STUDY WITH VISIBLE ATROPHY ON MRI IMAGE WITH POSSIBLE AD LEVEL (NOTE: LEFT BRAIN APPEARS AT RIGHT) [14]

DISCUSSION AND CONCLUSION

Over the last few years, hybrid or multimodality imaging has provided excellent opportunities to meet the needs inherent in the management of CNS diseases,

especially regarding neurodegenerative diseases. As a vector of development of the Neuroimaging area, AD has been extremely influenced by the results and imaging capabilities achieved by these techniques, in the knowledge

of its historical progression, early diagnosis and therapeutic evaluation.

PET-CT has been successfully applied in clinical practice with superior results to dedicated PET or CT options. However, the ability of MRI to obtain higher spatial resolution levels especially in soft tissues (especially critical factor in the context of the brain region) as well as the non-use of radiation made evident the need to include this technique as a new component to be included in a multimodality solution.

PET-MRI equipment for simultaneous data acquisition attempts to address this challenge by bridging the limitations of PET-CT at the brain level and improving the results achieved through a simultaneous real-time combination of quantitative neurophysiological information from PET and accurate MRI morphological information, with greater radiological safety. Therefore, the PET-MRI technique presents high potential for diagnostic and follow-up studies.

Progressive development in recent years, in terms of instrumentation and software for data acquisition and processing, has allowed the increase of soft tissue contrast and addition of functional information from the MRI through the blood diffusion, perfusion and oxygenation techniques, true multiplanar acquisition and reduced radiation exposure.

Despite these advantages, several challenges arise with PET-MRI, and its adoption in clinical practice has not yet been achieved mainly due to three major reasons: technical, clinical and financial problems.

The PET-MRI solution presents itself as a recent solution in the market, already with some weight in neurosciences research and in preclinical studies, with opened unaddressed challenges associated with the clinical level, still needing a complete technical evaluation and consequent clinical validation of its promising imaging characteristics.

ACKNOWLEDGMENTS

Authors gratefully acknowledge the funding of Project NORTE-01-0145-FEDER-000022 - SciTech - Science and Technology for Competitive and Sustainable Industries, co-financed by “Programa Operacional Regional do Norte” (NORTE2020), through “Fundo Europeu de Desenvolvimento Regional” (FEDER).

REFERENCES

- [1] Boellaard R, Quick HH. Current image acquisition options in PET/MR. *Semin Nucl Med.* 2015;45(3):192-200.
- [2] Catana C. Motion correction options in PET/MRI. *Semin Nucl Med.* 2015;45(3):212-23.
- [3] Cabello J, Lukas M, Rota Kops E, Ribeiro A, Shah NJ, Yakushev I, et al. Comparison between MRI-based attenuation correction methods for brain PET in dementia patients. *European Journal of Nuclear Medicine and Molecular Imaging.* 2016;1-11.
- [4] Boss A, Weiger M, Wiesinger F. Future image acquisition trends for PET/MRI. *Semin Nucl Med.* 2015;45(3):201-11.
- [5] Werner MK, Schmidt H, Schwenzer NF. MR/PET: A new challenge in hybrid imaging. *American Journal of Roentgenology.* 2012;199(2):272-7.
- [6] Mansi L, Ciarmiello A, Cuccurullo V. PET/MRI and the revolution of the third eye. *European Journal of Nuclear Medicine and Molecular Imaging.* 2012;39(10):1519-24.
- [7] Mansi L, Ciarmiello A. Perspectives on pet/mr imaging: Are we ready for clinical use. *Journal of Nuclear Medicine.* 2014;55(4):529-30.
- [8] Wagenknecht G, Kaiser HJ, Mottaghy FM, Herzog H. MRI for attenuation correction in PET: Methods and challenges. *Magnetic Resonance Materials in Physics, Biology and Medicine.* 2013;26(1):99-113.
- [9] Quick HH. Integrated PET/MR. *Journal of Magnetic Resonance Imaging.* 2014;39(2):243-58.
- [10] Wen L, Eberl S, Fulham M, Feng D. Recent Software Developments and Applications in Functional Imaging. *Current Pharmaceutical Biotechnology.* 2012;13(11):2166-81.
- [11] Bailey DL, Barthel H, Beyer T, Boellaard R, Gückel B, Hellwig D, et al. Summary report of the first international workshop on PET/MR imaging, March 19-23, 2012, Tübingen, Germany. *Molecular Imaging and Biology.* 2013;15(4):361-71.
- [12] Bailey DL, Barthel H, Beuthin-Baumann B, Beyer T, Bisdas S, Boellaard R, et al. Combined PET/MR: Where are we now? Summary report of the Second International Workshop on PET/MR Imaging April 8-12, 2013, Tübingen, Germany. *Molecular Imaging and Biology.* 2014;16(3):295-310.
- [13] Musiek ES, Borgwardt L, Saboury B, Alavi A. Hybrid pet imaging in neurologic disease: PET/MRI rather than PET/CT. *Current Medical Imaging Reviews.* 2011;7(3):193-201.
- [14] Barthel H, Schroeter ML, Hoffmann KT, Sabri O. PET/MR in dementia and other neurodegenerative diseases. *Seminars in Nuclear Medicine.* 2015;45(3):224-33.
- [15] Buchbender C, Heusner TA, Lauenstein TC, Bockisch A, Antoch G. Oncologic PET/MRI, part 1: Tumors of the brain, head and neck, chest, abdomen, and pelvis. *Journal of Nuclear Medicine.* 2012;53(6):928-38.
- [16] Catana C, Drzezga A, Heiss WD, Rosen BR. PET/MRI for neurologic applications. *Journal of Nuclear Medicine.* 2012;53(12):1916-25.
- [17] Drzezga A, Barthel H, Minoshima S, Sabri O. Potential clinical applications of PET/MR imaging in neurodegenerative diseases. *Journal of Nuclear Medicine.* 2014;55(6 SUPPL. 2):47S-55S.
- [18] Garibotto V, Heinzer S, Vulliemoz S, Guignard R, Wissmeyer M, Seeck M, et al. Clinical applications of hybrid PET/MRI in neuroimaging. *Clinical Nuclear Medicine.* 2013;38(1): e13-e8.
- [19] Garibotto V, Förster S, Haller S, Vargas MI, Drzezga A. Molecular neuroimaging with PET/MRI. *Clinical and Translational Imaging.* 2013;1(1):53-63.
- [20] Bagnoli S, Piaceri I, Sorbi S, Nacmias B. Advances in imaging-genetic relationships for Alzheimer's disease: clinical implications. *Neurodegenerative disease management.* 2014;4(1):73-81.
- [21] Fraioli F, Punwani S. Clinical and research applications of simultaneous positron emission tomography and MRI. *British Journal of Radiology.* 2014;87(1033).

- [22] Werner P, Barthel H, Drzezga A, Sabri O. Current status and future role of brain PET/MRI in clinical and research settings. *European Journal of Nuclear Medicine and Molecular Imaging*. 2015;42(3):512-26.
- [23] Mier W, Mier D. Advantages in functional imaging of the brain. *Frontiers in Human Neuroscience*. 2015;9(MAY).
- [24] Barbosa FDG, Von Schulthess G, Veit-Haibach P. Workflow in simultaneous PET/MRI. *Seminars in Nuclear Medicine*. 2015;45(4):332-44.
- [25] Martinez-Möller A, Eiber M, Nekolla SG, Souvatzoglou M, Drzezga A, Ziegler S, et al. Workflow and scan protocol considerations for integrated whole-body PET/MRI in oncology. *Journal of Nuclear Medicine*. 2012;53(9):1415-26.
- [26] Queiroz MA, Huellner MW. PET/MR in cancers of the head and neck. *Semin Nucl Med*. 2015;45(3):248-65.
- [27] von Schulthess GK, Veit-Haibach P. Workflow Considerations in PET/MR Imaging. *Journal of nuclear medicine: official publication, Society of Nuclear Medicine*. 2014;55(Supplement 2):19s-24s.
- [28] von Schulthess GK, Veit-Haibach P. Guest editorial. *Seminars in Nuclear Medicine*. 2015;45(3):189-91.
- [29] Weber WA. PET/MR imaging: A critical appraisal. *Journal of Nuclear Medicine*. 2014;55(6 SUPPL. 2).