

Semi-automatic quantification of the epicardial fat in CT images

Bruno Figueiredo & Jorge G. Barbosa

Lab. de Inteligência Artificial e Ciência dos Computadores

Universidade do Porto, Faculdade de Engenharia, Dep. de Engenharia Informática

Rua Dr. Roberto Frias, 4200-465 Porto, Portugal

(jbarbosa@fe.up.pt)

Nuno Bettencourt

Departamento de Cardiologia, Centro Hospitalar de Gaia V.N. Gaia, Portugal

João Manuel R.S. Tavares

Instituto de Engenharia Mecânica e Gestão Industrial, Campus da FEUP, Portugal

U. do Porto, Faculdade de Engenharia, Dep. de Eng. Mecânica e Gestão Industrial

Rua Dr. Roberto Frias, 4200-465 Porto, Portugal

In this work we present a technique to automatically or semi-automatically quantify the epicardial fat in non-contrasted Computed Tomography (CT) images. In CT images, the epicardial fat is very close to the pericardial fat, distinguished only by the pericardium. The pericardium appears in the image as a very thin line, very hard to discriminate. To enhance the pericardium line and to remove noise as well as higher intensities due to calcifications, some pre-processing was applied, namely region growing, thresholding and average filtering techniques. To detect the pericardium line an algorithm was developed that considers the heart anatomy to find control points belonging to that line. From the points detected an interpolation was done based on the cubic spline method. This method was also improved to avoid incorrect interpolation that occurs when one of the coordinates of the points is repeated. After having the line delineation, the pixels below the line were counted, considering only the pixels in the fat window (-190 to -30 Hounsfield Units). In 10 images tested, in 4 the system fully automatically returned the correct value for epicardial fat. In the other 6 the system needed a small correction by moving 1 or 2 points to return the correct value of epicardial fat. The values of the automatic quantification were compared to the values obtained by the manual process, having 10% as maximum error allowed. We concluded that this method is able to, automatically or with a small interaction, return the value of the epicardial fat, for the non contrast CT images tested.

1 INTRODUCTION

Obesity is recognized as an important risk factor for the development of cardiovascular disease (Visscher et al. 2001; Hubert et al. 1983; Manson et al. 1990). The quantification of visceral fat (fat surrounding the internal viscera), in contrast to the subcutaneous fat (which is deposited under the skin), shown to correlate very well with the development of atherosclerotic disease and with the parameters of the metabolic syndrome. Some methods were therefore developed in order to quantify the non-invasive fat composition assessing total body fat and visceral tissue in particular (Jeong et al. 2007).

The fat used for quantification of visceral fat is the visceral abdominal tissue. Borkan (Borkan et al. 1982) describes a method for performing this quantification by CT.

The epicardial fat is a deposition of visceral fat that surrounds the heart, accumulating mainly in the atrio-ventricular and interventricular grooves, surrounding the epicardial coronary arteries (Manson et al. 1990).

Not much is known about the true role and metabolic pathophysiology of epicardial fat, however, recent data suggest its involvement in the development and progression of coronary atheroscle-

rosis (Iacobellis et al. 2005). The epicardial fat produces numerous cytokines and proteins associated with atherosclerosis (Mazurek et al. 2003). This, coupled with the lack of real anatomical barrier between the tissue and the coronary arteries suggests a pro-atherogenic effect directly on the vessels.

From long time the CT has been used to quantify the deposition of visceral fat. This evaluation is performed at a single cut of the abdominal CT. Given the recent developments in CT and its increased application to the region of the heart, there has been an increasing interest in quantifying the deposition of fat on the heart. Some quantification processes have been applied as shown by Gorter et al (Gorter et al. 2008). However, these processes are mostly manual requiring a significant post-processing time. Attempts to automate this task have had some success and it is possible to quantify pericardial fat automatically, as described by Dey (Dey et al. 2008). However, these methods measure the total fat on the heart, without distinguishing the epicardial fat.

Due to the clinical interest in the measurement of epicardial fat and due to the lack of a method that allows its quantification in an automatic way, in this paper it is presented a method that can in some cases quantify automatically the epicardial fat and in others requires only a minimal user intervention.

2 FAT QUANTIFICATION METHOD

The process to automate the measurement of epicardial fat was separated into two parts. First, the image is preprocessed in order to remove the data that could mislead the detection of the pericardium, and the second part is the segmentation of the pericardium and the subsequent quantification of fat.

In this study, the images considered were first prepared with the method described by Dey (Dey et al. 2008) that removes all other structures apart from the heart, as shown in Figure 1a.

The preprocessing step of the algorithm to segment the pericardium is based on the fact that different tissues have different Hounsfield Units (HU) which is a linear transformation of the original linear attenuation coefficient of each tissue (Borkan et al. 1982). For the fat it is considered a range from -30 to -190 HU (Dey et al. 2008). The preprocessing algorithm is composed by the following steps: a region growing technique to detect the cardiac muscle; a threshold to remove high intensity points because they do not represent the muscle; a mean filter to reduce noise. Figure 1b shows the result of the region growing step that start in the center of the image and grows until it reaches the epicardial fat that has different intensities (HU). This pocket of fat also avoids the pericardium line to be removed. Figure 1c shows the image after removing the cardiac muscle. This image still has

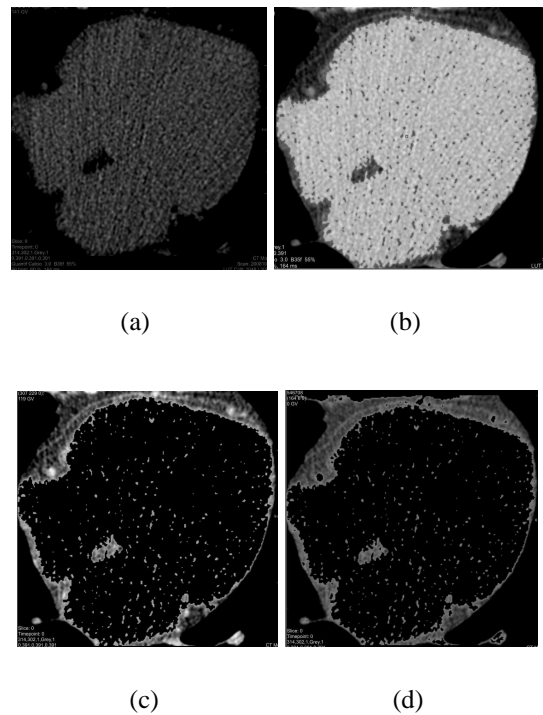


Figure 1: Preprocessing steps; a) non-contrasted image; b) muscle segmentation; c) after muscle removing d) final image

some artifacts that can be removed by a threshold filter for higher intensities that will not affect the fat and the pericardium line. Figure 1d shows the final result after applying the threshold and a mean filter for noise attenuation.

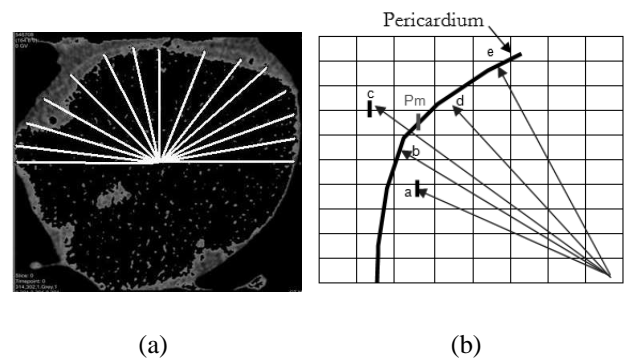


Figure 2: Pericardium segmentation a) detection of maximum values along a direction from the center; b) computation of a pericardium point

The pericardium is a very thin line on the image of Figure 1d which difficults its segmentation. Despite the great interest to quantify only the epicardial fat as described in (Mazurek et al. 2003) there is no method to do it automatically. The pericardium is surrounded by fat which have lower intensity levels on the image. It is that difference in intensity, among other characteristics, such as the pericardial line being set mainly in the anterior region of the heart as well as its shape

having in the image a rounded appearance, that the segmentation algorithm is based.

The segmentation algorithm sweeps the anterior region from 0 to 180 degrees registering the higher intensity point along each direction with a step of 5 degrees as shown in Figure 2a. For each of these main directions it is computed the maximum point on the directions from -5 to +5 degrees. From these 10 points it is computed the mean and standard deviation of the coordinates, as illustrated in Figure 2b where P_m is the mean position. These images have a significant amount of noise; therefore the mean points that exceed a given standard deviation, 10 in this study, were rejected. Figure 3 shows the application of the algorithm.

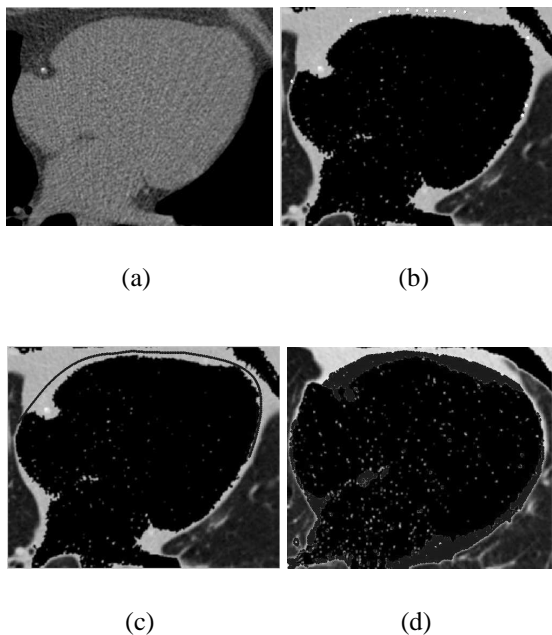


Figure 3: Pericardium segmentation a) initial image; b) points detected; c) pericardium line after spline interpolation; d) fat quantification

Figure 3a shows the original image and 3b the points detected. Only 15 points were selected to define the pericardium. All others were rejected due to noise that results in standard deviations greater than 10. However these 15 points are enough in this case to define correctly the pericardium line as shown in Figure 3c. This line is obtained by an improved spline interpolation that deals with repeated values on the x coordinate.

The fat quantification shown in Figure 3d is obtained by considering all pixels below the pericardium line with intensities in the fat range, from -190HU to -30HU.

3 RESULTS

The results of automatic quantification obtained were compared with results obtained manually, that were

considered as reference values. However, a variability in the manual measures of 10.4% were obtained for the same set of images for 3 different operators. This variability will be considered as acceptable variability in the values automatically obtained when compared with the values of the manual procedure.

The algorithm was tested on 10 images with different cardiac forms and distribution of fat, represented in Table 1 by the manual measurement. There are 4 images in which the system automatically detects the epicardial fat. In the other 6 cases the system automatically detects much of epicardial fat although it needs a slight correction. With this small correction the system is properly adjusted to the region of the epicardial fat. Table 5.1 compares the values obtained manually with the segmentation algorithm described here. The manual measures are average values of 3 operators. The column of points adjusted shows the adjustment required by the user to obtain the presented result of the semi-automatic algorithm.

Manual (mm^2)	Semi-automatic (mm^2)	Difference (%)	Points adjusted
1221	1211	0.86	0
687	686	0.04	1
770	705	8.44	0
1384	1321	4.58	2
2379	2379	0.00	2
2580	2501	3.07	2
608	662	8.96	0
1087	1170	7.53	0
1376	1422	3.28	2
1684	1590	5.60	2

Table 1: Comparison between manual and semi-automatic method

4 CONCLUSIONS

Given the values obtained by the method presented in this paper, we conclude that it is not robust enough to operate in a fully automatic mode for all cases. However, with a small interaction with the user in setting up 2 points, it achieves identical results as the manual method for all tested cases. In fact, in 4 of the 10 images the fat was quantified in a fully automatic way. In the remaining cases it was obtained by a semi-automatic quantification.

It can be observed that the average error of the proposed method to the manual one is around 4%. This is less than the deviation observed on the epicardial fat quantification performed by different operators. There was a maximum deviation of 8.96%, compared to the 10.4% inter-operator, and in 3 cases the deviation was less than 1%.

REFERENCES

- Borkan, G., S. Gerzof, and A. R. *et al.* (1982). Assessment of abdominal fat content by computed tomography. *American Journal of Clinical Nutrition* 36(1), 172–177.
- Dey, D., Y. Suzuki, and S. S. *et al.* (2008, February). Automated quantitation of pericardiac fat from noncontrast ct. *Investigative Radiology* 43(2), 145–153.
- Gorter, P., A. van Lindert, and A. de Vos *et al.* (2008). Quantification of epicardial and pericoronary fat using cardiac computed tomography; reproducibility and relation with obesity and metabolic syndrome in patients suspected of coronary artery disease. *Atherosclerosis* 197(2), 896–903.
- Hubert, H., M. Feinleib, and P. M. *et al.* (1983). Obesity as an independent risk factor for cardiovascular disease: A 26-year followup of participants in the framingham heart study. *Circulation* 67(5), 968–977.
- Iacobellis, G., D. Pistilli, and M. G. *et al.* (2005, March). Adiponectin expression in human epicardial adipose tissue in vivo is lower in patients with coronary artery disease. *Cytokine* 29(6), 251–255.
- Jeong, J., M. Jeong, and K. Y. *et al.* (2007, April). Echocardiographic epicardial fat thickness and coronary artery disease. *Circulation* 71(4), 536–539.
- Manson, J., G. Colditz, and M. S. *et al.* (1990, March). A prospective study of obesity and risk of coronary heart disease in women. *New England Journal of Medicine* 322(13), 882–889.
- Mazurek, T., L. Zhang, and A. Z. *et al.* (2003, November). Human epicardial adipose tissue is a source of inflammatory mediators. *Circulation* 108(20), 2460–2466.
- Visscher, T., J. Seidell, and A. M. *et al.* (2001, November). A comparison of body mass index, waist-hip ratio and waist circumference as predictors of all-cause mortality among the elderly: the rotterdam study. *International Journal of Obesity* 25(11), 1730–1735.